

Histological and CBCT evaluation of a pulpotomised primary molar using calcium enriched mixture cement

L. Mehrdad · B. Malekafzali · F. Shekarchi ·
Y. Safi · S. Asgary

Received: 24 September 2012 / Accepted: 21 February 2013 / Published online: 18 April 2013
© European Academy of Paediatric Dentistry 2013

Abstract

Background Pulpotomy is one of the most commonly used treatments for retaining pulpally involved primary molar teeth in order to prevent tooth extraction and maintain space within the jaws. A recent randomised clinical trial found that calcium enriched mixture (CEM) cement demonstrated favourable 2-year treatment outcomes for pulpotomy of carious primary molars comparable with mineral trioxide aggregate (MTA). The use of cone beam computer tomography (CBCT) has not previously been used to evaluate pulpotomy and histological outcomes.

Case report A coronal pulpotomy was performed on a carious maxillary first primary molar in a 7-year-old child with non-contributory medical history. Following haemostasis, the radicular pulp was covered with 2–3 mm of CEM and the tooth restored.

Follow-up At the 2-year follow-up appointment, clinical/radiographic examinations of the pulpotomised tooth

revealed that vital pulp therapy was successful in maintaining the tooth asymptomatic; however, the first maxillary molars had to be extracted for orthodontic reasons. CBCT and histological examinations showed thick/complete calcific bridges with tubular dentine at the amputation sites. The underlying dental pulp had normal structure and was un-inflamed.

Conclusion Based on these findings, it seems that CEM cement can induce a favourable biological response in dental pulps of primary teeth and CBCT may be useful to evaluate pulpotomy outcomes.

Keywords Calcium enriched mixture · CEM cement · Deciduous · Dentinogenesis · Histological · Imaging, Three-dimensional · Pulpotomy

Background

Pulpotomy is one of the most commonly used treatments for retaining pulpally involved primary molar teeth to prevent tooth extraction and maintain space within the jaws (Trope 2008). One of the most popular pulpotomy medicaments that have been used for many years has been formocresol. One current school of thought has some concerns with this devitalisation pulpotomy agent as results have shown that it might cause pulpal inflammation and necrosis (Garcia-Godoy et al. 1982). Formocresol has cytotoxicity (Hill et al. 1991), mutagenic and carcinogenic potential (Myers et al. 1983) with negative systemic confusions (Lewis and Chestner 1981) and immunologic responses (Wu et al. 1989). To overcome the disadvantages and limitations of formocresol, numerous alternatives have been introduced i.e. ferric sulphate (Peng et al. 2007), mineral trioxide aggregate (MTA) (Peng et al. 2006) and

L. Mehrdad · B. Malekafzali · F. Shekarchi
Dental Research Center, Research Institute of Dental Sciences,
Shahid Beheshti University of Medical Sciences, Tehran, Iran

B. Malekafzali (✉)
Department of Paediatric Dentistry, Dental Research Center,
Shahid Beheshti University of Medical Sciences, Tehran, Iran
e-mail: beheshtehm@yahoo.com

Y. Safi
Department of Oral and Maxillofacial Radiology, Dental School,
Shahid Beheshti University of Medical Sciences, Tehran, Iran

S. Asgary
Iranian Center for Endodontic Research, Research Institute of
Dental Sciences, Shahid Beheshti University of Medical
Sciences, Tehran, Iran

calcium enriched mixture (CEM) biomaterial (Malekafzali et al. 2011).

CEM cement has been introduced as a root-end filling material (Asgary et al. 2008); however, it has demonstrated favourable treatment outcomes in various vital pulp therapies such as direct pulpal capping of human permanent (Zarrabi et al. 2010, 2011; Asgary et al. 2012) and primary molar teeth (Fallahinejad Ghajari et al. 2010). It has also shown positive results with apexogenesis and maturation of trauma- and caries-exposed immature permanent teeth (Nosrat and Asgary 2010; Nosrat et al. 2013), as well as pulpotomy of permanent human mature molars with irreversible pulpitis (Asgary et al. 2013), and revitalisation procedure (Nosrat et al. 2011). Many histological studies have shown re-establishment of normal periodontium and cementogenesis over the novel endodontic biomaterial (Asgary et al. 2010; Samiee et al. 2010), osteogenesis (Rahimi et al. 2012) and dentine bridge formation. Mixed cement releases indigenous calcium and phosphate ions to form hydroxyapatite (Asgary et al. 2009).

Cone beam computed tomography (CBCT) has facilitated the work of dental clinicians to evaluate endodontic anatomy/structures with a new approach and to provide more detailed and precise image information unachievable with conventional radiography (Cotton et al. 2007). Adding a third dimension has assisted in radiographic interpretation (Patel 2009); an important advantage of CBCT is that it allows clinicians to observe multiple slices of tooth objects.

A recent randomised clinical trial found that CEM demonstrated favourable 2-year treatment outcomes for pulpotomy of carious primary molars comparable to MTA (Malekafzali et al. 2011). According to the author's knowledge, there are no previous CBCT and histological reports evaluating pulpotomy with endodontic biomaterials in human primary molar teeth. The purpose of this report was to histologically and radiographically (CBCT) evaluate the response of human primary molar dental pulp to CEM pulpotomy.

Case report

A 7-year-old girl was referred for assessment by her orthodontist for extraction of her maxillary first primary molars. The tooth was pulpotomised 24 months previously using CEM cement. Clinical/radiographic examinations revealed no sign/symptoms of inflammation or infection. Before extraction, written informed consent was obtained from the parent. The extracted molar was stored in 10 % formalin. Upon fixation of the tooth, a dentine bridge formation was evaluated with conventional radiographs (Fig. 1) and a CBCT (Scanora 3D, Soredex, Finland) at a

tube voltage of 90 kVp, tube current of 4 mA, FOV of 6×6 and voxel size of 133 μm ; the amalgam restoration was removed before CBCT. After decalcification in 10 % nitric acid for 10 days, the specimen was rinsed with tap water for 1 h, followed by dehydration in ascending concentrations of alcohol, and then embedded in paraffin. Buccolingual sections were prepared with 6- μm thickness and stained with haematoxylin and eosin.

CBCT revealed a dentine bridge between root canal pulp and the pulpotomy biomaterial (Fig. 2). Histological observation with an optical microscope (Zeiss, Goettingen, Germany) showed deposition of a thick and complete layer of dentine bridge at the amputation site (Fig. 3). The newly formed dentine showed dentinal tubules and odontoblastic processes. The normal pulpal architectural patterns were largely preserved. The odontoblastic layer was also preserved, showing a continuous regular arrangement at the pulp–dentine junction.

Discussion

Formocresol is the traditional 'gold standard' pulpotomy agent for primary teeth; however, it causes devitalisation of the remaining pulp (Srinivasan et al. 2006). Therefore, the clinical and radiographic treatment outcomes have always been evaluated and the nature of the remaining pulp has not been assessed. Recently, new treatment perspectives have encouraged the use of biomaterials in primary teeth to induce biologic pulpal healing and repair (Fuks 2008). To date, there have been no histological and CBCT reports regarding the nature of dental pulp healing and calcific bridge formation in primary teeth treated with biomaterials. The clinical/radiographic success of this CEM pulpotomy-treated tooth provides the first CBCT and histological view of complete dentine bridge formation (regular dentine structure with dental tubules) between the CEM and pulp

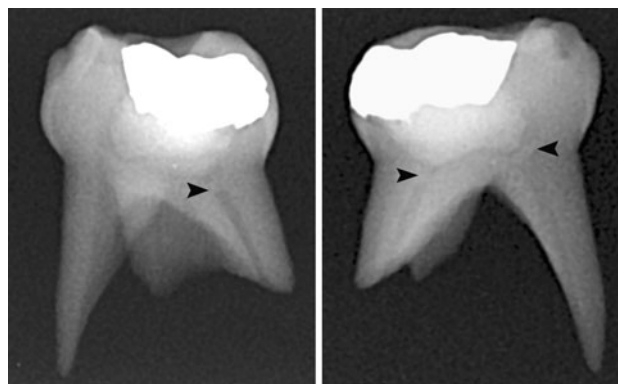


Fig. 1 Conventional radiographs demonstrating calcific bridges (black arrowhead) between radicular pulp and pulp capping biomaterial (CEM cement)

Fig. 2 CBCT images showing three-dimensional view of extracted maxillary first primary molar (*left*) and calcific barrier after sectioning (*centre*); two dimensional CBCT image (*right*) clearly demonstrates thick calcific bridge formation at the pulp-CEM junctions

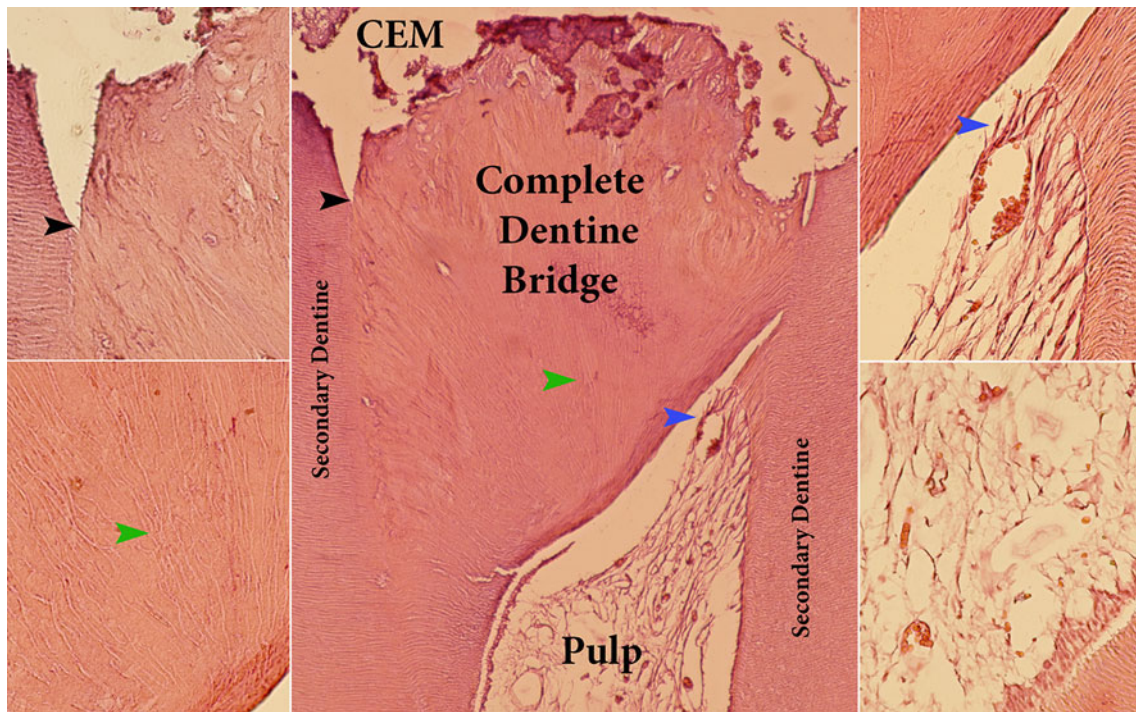
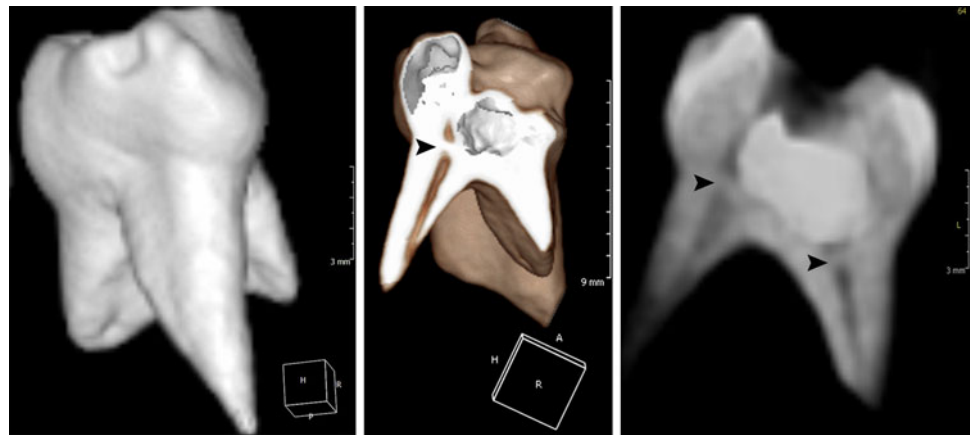


Fig. 3 Complete dentine bridge formed between pulp capping material (CEM; calcium enriched mixture cement) and radicular pulp tissue (*centre*), the boundaries of new bridge are clearly evident with secondary dentine (upper left; *black arrowheads*); it contains

dentinal tubules (lower left; *green arrowheads*). Odontoblasts and odontoblast-like cells (upper right; *blue arrowheads*) deposited dentine and the pulp is un-inflamed (lower right)

canals. Moreover, there were no tunnel defects associated with normal underlying pulp; it verifies a biologic success for pulpotomy treatment of primary molars using this novel biomaterial.

It is well established that dental pulp healing is directly related to the properties of the capping material. These include sealability, antimicrobial activity, and more significantly, induction of dentine formation, that is bioregeneration (Tziafas et al. 2000). CEM cement favourably prevents microleakage and has sealing ability superior to IRM but comparable with MTA; in addition, it was an effective antibacterial and antifungal agent (Kangarlou

et al. 2009). CEM cement creates a high pH environment and simultaneously releases calcium and phosphorus ions from indigenous sources. This mechanism facilitates the process of hydroxyapatite formation (Asgary et al. 2009); the pattern of calcium, phosphorus, and oxygen distribution in the surface of this cement is similar to dentine. Moreover, this cement is non-cytotoxic, and induces osteogenesis, cementogenesis and dentinogenesis. Therefore, it might be reasonable to hypothesize that it is biocompatible.

While the results of recent randomised clinical trials have the highest level of evidence (Malekafzali et al. 2011), histological confirmation using human primary teeth

will provide the final verification of the biological success of CEM cement. Based on the biological properties of this cement, in particular its tight seal, antimicrobial properties and biocompatibility, CEM might be a suitable biomaterial for pulpotomy of primary molars.

References

- Asgary S, Eghbal MJ, Parirokh M. Sealing ability of a novel endodontic cement as a root-end filling material. *J Biomed Mater Res A*. 2008;87:706–9.
- Asgary S, Eghbal MJ, Parirokh M, Ghoddsi J. Effect of two storage solutions on surface topography of two root-end fillings. *Aust Endod J*. 2009;35:147–52.
- Asgary S, Eghbal MJ, Ehsani S. Periradicular regeneration after endodontic surgery with calcium-enriched mixture cement in dogs. *J Endod*. 2010;36:837–41.
- Asgary S, Nosrat A, Homayounfar N. Periapical healing after direct pulp capping with calcium-enriched mixture cement: a case report. *Oper Dent*. 2012;37:571–5.
- Asgary S, Eghbal MJ, Ghoddsi J, Yazdani S. One-year results of vital pulp therapy in permanent molars with irreversible pulpitis: an ongoing multicenter, randomized, non-inferiority clinical trial. *Clin Oral Investig*. 2013;17:431–9.
- Cotton TP, Geisler TM, Holden DT, Schwartz SA, Schindler WG. Endodontic applications of cone-beam volumetric tomography. *J Endod*. 2007;33:1121–32.
- Fallahinejad Ghajari M, Asgharian Jeddi T, Iri S, Asgary S. Direct pulp-capping with calcium enriched mixture in primary molar teeth: a randomized clinical trial. *Iran Endod J*. 2010;5:23–6.
- Fuks AB. Vital pulp therapy with new materials for primary teeth: new directions and treatment perspectives. *J Endod*. 2008;34:S18–24.
- Garcia-Godoy F, Novakovic DP, Carvajal IN. Pulpal response to different application times of formocresol. *J Pedod*. 1982;6:176–93.
- Hill SD, Berry CW, Seale NS, Kaga M. Comparison of antimicrobial and cytotoxic effects of glutaraldehyde and formocresol. *Oral Surg Oral Med Oral Pathol*. 1991;71:89–95.
- Kangarlou A, Sofiabadi S, Yadegari Z, Asgary S. Antifungal effect of calcium enriched mixture (CEM) cement against *Candida albicans*. *Iran Endod J*. 2009;4:101–5.
- Lewis BB, Chestner SB. Formaldehyde in dentistry: a review of mutagenic and carcinogenic potential. *J Am Dent Assoc*. 1981;103:429–34.
- Malekafzali B, Shekarchi F, Asgary S. Treatment outcomes of pulpotomy in primary molars using two endodontic biomaterials. A 2-year randomised clinical trial. *Eur J Paediatr Dent*. 2011;12:189–93.
- Myers DR, Pashley DH, Whitford GM, McKinney RV. Tissue changes induced by the absorption of formocresol from pulpotomy sites in dogs. *Pediatr Dent*. 1983;5:6–8.
- Nosrat A, Asgary S. Apexogenesis treatment with a new endodontic cement: a case report. *J Endod*. 2010;36:912–4.
- Nosrat A, Seifi A, Asgary S. Regenerative endodontic treatment (revascularization) for necrotic immature permanent molars: a review and report of two cases with a new biomaterial. *J Endod*. 2011;37:562–7.
- Nosrat A, Seifi A, Asgary S. Pulpotomy in caries-exposed immature permanent molars using calcium-enriched mixture cement or mineral trioxide aggregate: a randomized clinical trial. *Int J Paediatr Dent*. 2013;23:56–63.
- Patel S. New dimensions in endodontic imaging: Part 2. Cone beam computed tomography. *Int Endod J*. 2009;42:463–75.
- Peng L, Ye L, Tan H, Zhou X. Evaluation of the formocresol versus mineral trioxide aggregate primary molar pulpotomy: a meta-analysis. *Oral Surg Oral Med Oral Pathol Oral Radiol Endod*. 2006;102:e40–4.
- Peng L, Ye L, Guo X, et al. Evaluation of formocresol versus ferric sulphate primary molar pulpotomy: a systematic review and meta-analysis. *Int Endod J*. 2007;40:751–7.
- Rahimi S, Mokhtari H, Shahi S et al. Osseous reaction to implantation of two endodontic cements: mineral trioxide aggregate (MTA) and calcium enriched mixture (CEM). *Med Oral Patol Oral Cir Bucal*. 2012;17(5):e907–11.
- Samiee M, Eghbal MJ, Parirokh M, Abbas FM, Asgary S. Repair of furcal perforation using a new endodontic cement. *Clin Oral Investig*. 2010;14:653–8.
- Srinivasan V, Patchett CL, Waterhouse PJ. Is there life after Buckley's Formocresol? Part I—a narrative review of alternative interventions and materials. *Int J Paediatr Dent*. 2006;16:117–27.
- Trope M. Regenerative potential of dental pulp. *Pediatr Dent*. 2008;30:206–10.
- Tziafas D, Smith AJ, Lesot H. Designing new treatment strategies in vital pulp therapy. *J Dent*. 2000;28:77–92.
- Wu MK, Wang ME, Chang SP. Antibody formation to dog pulp tissue altered by a paste containing paraformaldehyde. *Int Endod J*. 1989;22:133–7.
- Zarrabi MH, Javidi M, Jafarian AH, Joushan B. Histologic assessment of human pulp response to capping with mineral trioxide aggregate and a novel endodontic cement. *J Endod*. 2010;36:1778–81.
- Zarrabi MH, Javidi M, Jafarian AH, Joushan B. Immunohistochemical expression of fibronectin and tenascin in human tooth pulp capped with mineral trioxide aggregate and a novel endodontic cement. *J Endod*. 2011;37:1613–8.