

Prevalence, dimension and location of retromolar canal on cone beam computed tomography: An Analytical cross sectional study

Khalil Sarikhani Khorami ¹, Fatemeh Ezoddini Ardakani ², Yaser SAfi ³, Motahare Baghestani^{4*}

1. Assistant Professor Assistant Professor, Department of Oral and Maxillofacial Radiology, Faculty of Dentistry, Shahid Sadoughi University of Medical Sciences, Yazd, Iran.
2. Professor Professor, Department of Oral and Maxillofacial Radiology, Faculty of Dentistry, Shahid Sadoughi University of Medical Sciences, Yazd, Iran.
3. Associate Professor Associate Professor, Department of Oral and Maxillofacial Radiology, School of Dentistry, Shahid Beheshti University of Medical Sciences. Tehran, Iran.
4. Post graduated Student Post graduated Student, Department of Oral and Maxillofacial Radiology, Faculty of Dentistry, Shahid Sadoughi University, Yazd, Iran.

Article Type:
Original Article

***Correspondence:**

Motahare Baghestani

Post graduated Student Post graduated Student,
Department of Oral and Maxillofacial Radiology,
Faculty of Dentistry, Shahid Sadoughi University, Yazd, Iran.

baghestani.motahare@yahoo.com



Abstract

Background and objectives: The retromolar canal is an anatomical variant that needs consideration in local anesthesia and surgical procedures involving the retromolar area. Complications such as local anesthetic insufficiency, a sensory deficit, hemorrhage and traumatic neuroma may arise in the absence of recognition of these variants. The aim of this study is to determine the prevalence and course of retromolar canal in the Iranian population.

Methods: This study is a descriptive cross sectional study. The cross sectional sagittal and three dimensional images from volumetric CBCT. data of 270 patients were reconstructed using on demand imaging analysis software. Retromolar canals were classified into two types according to the courses. The width and location (distance from the third molar) of retromolar canals were evaluated. Results were analyzed with SPSS 20 software and were assessed using the t_test and chi_square test.

Results: Retromolar canal was observed in 9/25 % of patients. The mean width of the retromolar foramen was 1/43 mm, and the mean distance from anterior border of retromolar foramen to the distal CEJ of the second molar was 13/33 mm.

Conclusion: The prevalence of retromolar canals in the Iranian population was lower than that was reported in previous studies. It can be observed in 9/25 % of Iranian patients. Damage to the retromolar canal may be unavoidable during surgical procedures may result in paresthesia, excessive bleeding, postoperative hematoma, or traumatic neuroma. Therefore, the clinician must pay particular attention to the identification of a retromolar canal by preoperative radiographic examination and additional CBCT scanning is recommended.

Keywords: CBCT; Retromolar canal; Retromolar foramen; Mandibular canal; Inferior alveolar canal

Introduction

Retromolar canal (RMC) is separated from the main mandibular canal in the distal region of the third molar and is traversed with a

posterior-upper curvature behind the third molar and inserted into the retromolar foramen (RMF) located in the retromolar triangle at the posterior aspect of the third molar(1-3) (Figure 1).

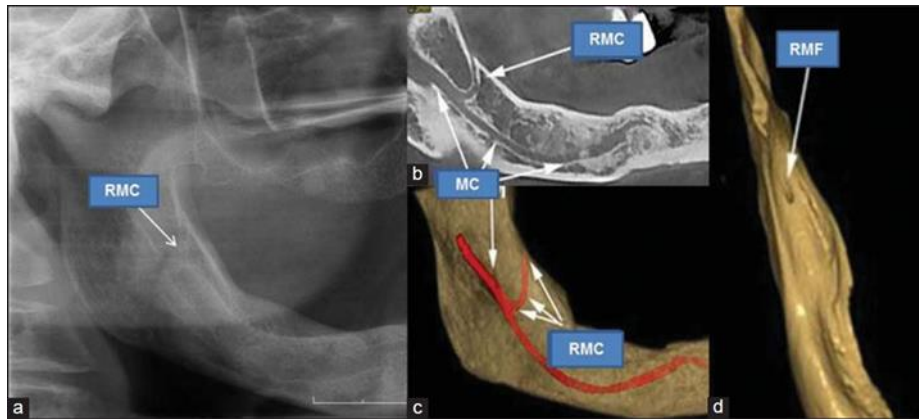


Figure1:Retromolar canal and retromolar foramen.

RMC contains multiple arteries and veins and strands of myelinated nerves (4, 5). In about 10-20% of cases, this anatomical distinction can lead to failure of mandibular block (6, 7).

For this reason, special attention should be paid to RMC in surgical procedures in the posterior aspect of mandible. Complications of disregarding RMC in surgeries include nerve damage, sensory defects, bleeding and

traumatic neuroma (2, 8, 9). Compression of neurovascular bundles of RMC nerves in the retromolar fossa region by prosthetics causes discomfort in the elderly who have resorption of alveolar bone (10). The canal may also act as a route for spread of regional infections (10). Sometimes, the presence of RMC in the panoramic view mimics the appearance of a cystic pathological lesion and can mislead the clinician (Figure 2).

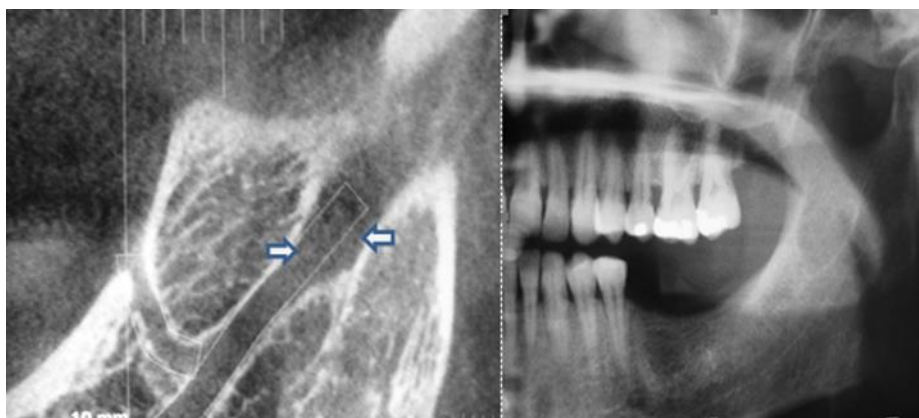


Figure2: Confusing appearance of RMC in the panoramic view.

On the left side of the digital panoramic view, there is a cystic lesion (arrows) in the mandibular ramus. On the right side, CBCT of the same patient shows that the observed panoramic view was not cyst, but the circular shape created by RMC and inferior alveolar canal wall opacity lead to this mistake. Therefore, it is particularly important to recognize the presence and identify RMC route before performing mandibular surgeries. RMC is generally described as a subtype of the bifid mandibular canal, called Retromolar type. Chavez-Lomeli et al suggested that bifid mandibular canal was created as a result of inadequate fusion of separate inferior alveolar nerves (incisor, primary and permanent molars) during embryonic development (8). The high prevalence of RMC in some geographical areas requires special attention (2, 4, 10). Some studies suggest that its frequency depends on race (11). In a study of 253 RMCs observed in CBCT, only 29 canals were observed in panoramic radiography (12). In another study, the same result was obtained (13). It was also concluded that CBCT imaging method is more appropriate than panoramic imaging to detect RMC because of 3D dimensionality (12). Considering the importance of detecting RMC and few studies conducted in Iran in this regard, this study tends to examine route and frequency of RMC in CBCT images in Iranian population.

Materials and Methods

This was a descriptive, cross-sectional study. The studied population consisted of radiographic CBCT images of mandible of 270 patients who referred to a maxillofacial radiology clinic in Tehran (2011-2014) to perform imaging for impacted wisdom teeth

surgeries, implantation and other therapies. Images must include posterior mandibular region. Every image that had a fracture in this region was excluded. Sampling was done randomly from 3000 CBCT. Given the 95% confidence level and 20% prevalence of RMC in CBCT cases and 5% error, the minimum sample size was 250 samples.

$$N = ((Z_{1-\alpha/2})^2 \times P(1-P)) / d^2$$

The CBDC imaging machine (Sordex scanora 3D, Helsinki, made in Finland) had 7.5×10 cm FOV, 90 KVP, 10 MA exposure condition, 16 s, and 0.2 mm Voxel size. Images were analysed by on-demand software. Multiple axial and multiplanar sections were made and RMC (if existed) was shown and examined. Measurements were carried out in cross-sectional and reconstructed panoramic images. All RMCs were classified based on their routes. The incidence of RMC in men and women separately and its overall incidence were evaluated. In this study, like most studies, the frequency of canals was not measured at different ages due to the fact that RMC was an anatomic variation. Canal width was measured when branching from the inferior alveolar canal in the reconstructed panoramic image (Figure 3). The canal width was measured when leaving the retromolar foramen in the reconstructed panoramic image (Figure 3). The existence of retromolar nerve in the retromolar fossa was determined in cross-sectional sections by dividing the fossa into two buccal and lingual halves (Figure 4). The distance from the most anterior part of retromolar foramen to distal CEJ of the second molar was measured (Figure 5).

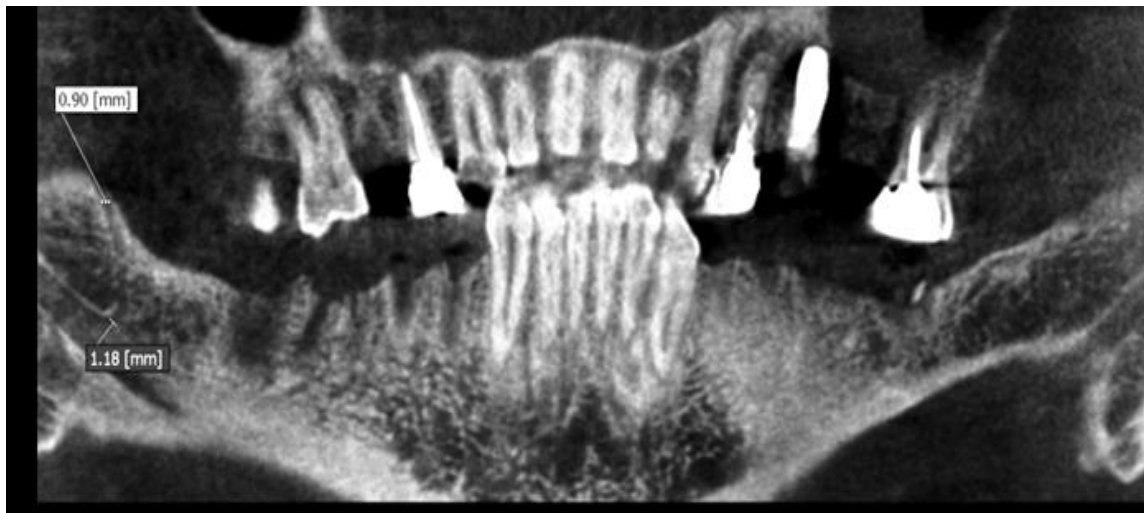

Figure 3: Measuring retromolar canal width when branching from the inferior alveolar canal and when leaving the retromolar foramen in the reconstructed panoramic image.

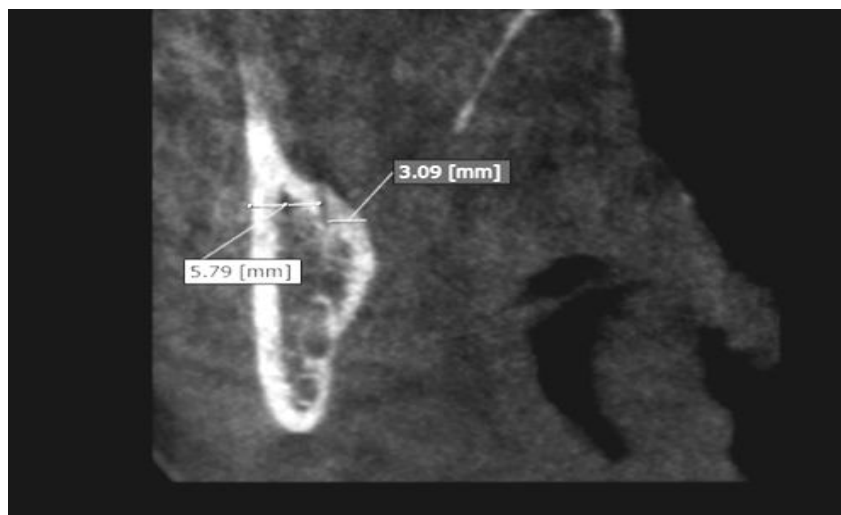

Figure 4: Measuring the distance between retromolar canal borders and buccal and lingual cortex.

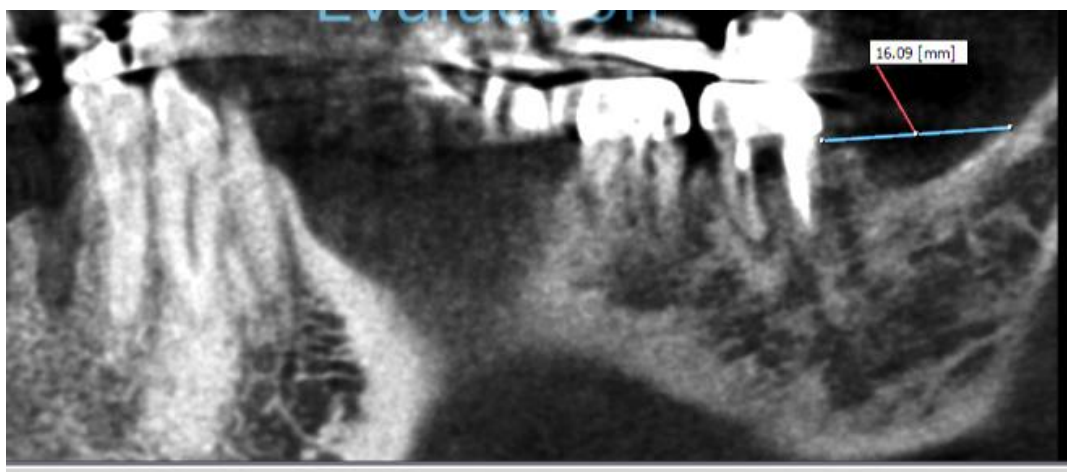


Figure 5: Measuring the distance from retromolar foramen to distal CEJ of the second molar.

RMC was classified according to the route to the following two groups: Type I: The most common type of RMC. In this case, RMC in the posterior third molar is separated from the main canal of the mandible and ends through posterior-upper route to retromolar foramen in the retromolar fossa region. In this type of canal, the distance from the anterior most point of foramen to distal CEJ of the second molar, as well as width of the retromolar foramen and width of RMC were measured when separating from the main canal of the mandible (Figure 6).

Type II: In this case, RMC in the molar area, or a little bit behind, is separated from the main canal of the mandible and reaches the periodontal ligament of the inferior molar teeth, particularly the third molar; in this type of canal, the foramen is not seen in the retromolar fossa. In the absence of molar teeth, this canal disappears in bone through a short route after separating from the inferior alveolar canal and its exit from the retromolar foramen was not proved in CBCT images. In this type of canal, the canal width was measured when separating from the main canal of the mandible (Figure 7).

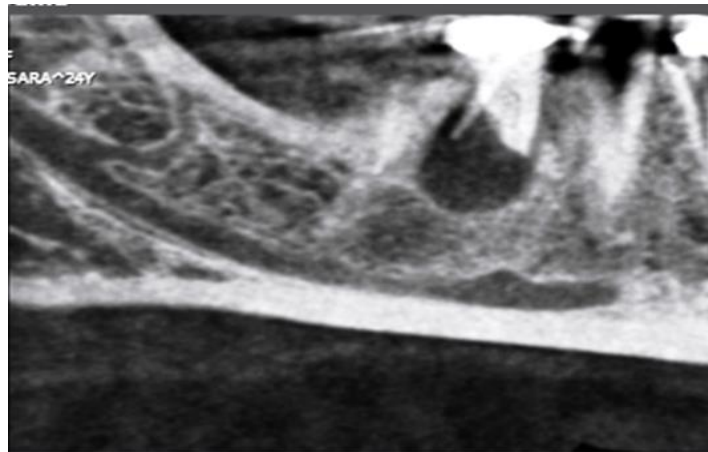


Figure6: Type 1 of retromolar canal

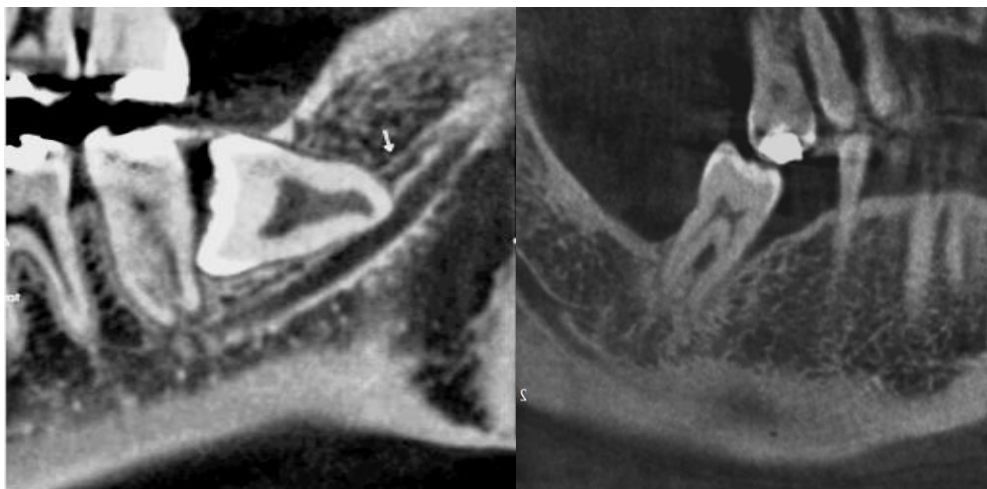


Figure7: Type 2 of retromolar canal

Data Analysis

The data was written for each sample in a data collection form set for this purpose. Data was collected and inserted into SPSS-20 software and described using descriptive statistics including mean, percentage and frequency. Chi-square test and T-test were used to analyze the results.

Results

A total of 270 samples were studied. Out of 270 samples (540 regions in the left and right mandible), 121 (44.81%) were female and 149 (55.19%) were male. The age range of participants was at least 17 and at most 87 years. Out of the samples, 25 (9.25%) patients

had RMC. Of these, 6 (2.22%) had bilateral canal and 19 (7.03%) had unilateral canal. Out of 19 patients with unilateral canal, 10 cases had left canal and 9 cases had right canal. The frequency of canal in the left and right mandible was 31 (5.7%). Table 1-3 shows distribution of canal frequency by gender. The frequency distribution of canal in male and female genders was not statistically significant in the chi-square test (P-value=0.67) (Table 1). According to the frequency distribution table, the majority of RMCs were type I (Table 2). Frequency distribution of RMC indicated that the prevalence of RMC was 9.25% in the studied people. Moreover, 7.03% had unilateral canal and 2.22% had bilateral canal (Table 3).

Table1: Prevalence of the retromolar canal and its gender distribution in the study sample.

	Male (Number:149)	Female (Number:121)
Retromolar Canal presence	15(10/06)	10(8/26%)
Retromolar canal absence	134(89/94)	111(91/74)
P-value= 0/67		

Table2: Prevalence of the retromolar canal based on canal type in the study sample.

Type of retromolar canal	Prevalence of retromolar canal based on region	Percent
Type I	19	61/3%
Type II	12	38/7%
Total	31	100%

Table 3: Prevalence of the retromolar canal in the study sample.

Retromolar canal	(Individual) (%)	(Region) (%)
Total number	270(100%)	540(100%)
Retromolar Canal absence	245(90/75)	509(3/94)
Retromolar Canal presence	25(9/25%)	31(5/7%)
Uni lateral retromolar canal	19(7/03%)	19(3/5%)
Bi lateral retromolar canal	6(2/22%)	12(2/22%)

According to the table below and t-test, the mean width of retromolar foramen was not statistically significant in males and females (P-value>0.05), as shown in Table 4. The mean width of retromolar foramen when separating from inferior alveolar canal was not statistically different in men and women (P-value>0.05), as shown in Table 5. The mean distance from retromolar foramen to

distal CEJ of the second molar was not statistically significant in men and women (P-value<0.05) (Table 6). Table 7 shows buccolingual inclination of retromolar foramen in the type I canal. After splitting the alveolar ridge into buccal and lingual halves, 57.9% of foramen were in the lingual half of the ridge (Table 7).

Table 4: The mean width of retromolar foramen by gender in the study sample.

	Male	Female	Total mean
Mean ± Standard deviation width(mm) RMF	1/44±0/39	1/42±0/52	1/43±0/45

Table 5: The mean width of retromolar foramen when separating from inferior alveolar canal by gender in the study sample.

	Male	Female	Total mean
Mean ± Standard deviation width(mm) RMF	1/88±0/64	1/71±0/59	1/81±0/61

Table 6: The mean Distance from the retromolar foramen to the cemento enamel junction of second molar.

	Male	Female	Total mean
Mean ± Standard deviation Distance to second molar(mm)	13/94±1/84	12/64±1/55	13/33±1/69

Table 7: Buccolingual inclination of type I retromolar canal in the study sample.

	Retromolar foramen	Lingual inclination	Buccal inclination
Number	19	11	8
Percent	100%	57/9%	42/1%

Discussion

In summary, findings of the recent study showed that 25 cases (9.25%) had at least one RMC. Of these, 6 (2.22%) had bilateral canal and 19 (7.03%) had unilateral canal. Among these 19 cases, 10 canals were located on the left and 9 were on the right. The canal side frequency was 31 (5.7%).

The findings showed that the prevalence of RMC in the Iranian population was significant, but as comparison shows, other studies show reported that the prevalence of RMC is higher than 10% in other parts of the world. So far, studies on RMC have been done in two methods: using Cadaver and using radiography of patients. In the studies on cadaver's dried skull or mandible, the following results were obtained:

Group 1: Prevalence of RMC above 40%; Schejtman et al. reported 73% prevalence (14), Kawai et al. reported 52% prevalence (2) and the study done in Iran by Kalantar Motamedi et al. reported 40.4% prevalence (4).

Group 2: Prevalence of RMC less than 30%; Naranaya et al reported 21.9% prevalence (15), Pyle et al reported 7.8% prevalence (16), Kumar et al reported 17.3% prevalence (17), Athavale et al reported 14.08% prevalence (18), Meera Jacob et al reported 12.5% prevalence (19), Jawed Akhtar et al reported

14.7% prevalence (20), Alves et al reported 18.6% prevalence (21), Sawyer et al reported 7.7% prevalence (22) and Kumar Potu et al reported 11.7% prevalence (3).

However, macroscopic studies done on Cadaver is more difficult than radiographic studies and it is possible to mistake spongy bone marrow spaces with RMC with a diameter of about 1 mm; but in 3D radiographic images, particularly CBCT, it is more practical and accurate to find the canal and its route. Thus, the canal can be found dynamically in CBCT images and likelihood of mistake can be reduced. Due to differences in the methodology, the results of the studies done on Cadaver were not comparable with the results of current study, which was performed using CBCT imaging. In a study in South Korea by S-S Han et al (2014), 446 patients were screened for CBCT images (8). The prevalence of RMC was 8.5%. In this study, there was no statistically significant relationship between gender and frequency of RMC. In the present study, the frequency of RMC was determined at 9.25%. There was no significant relationship between gender and frequency of RMC. The similarities in results of the two studies were due to the same methodology by CBCT images and high sample size in two studies. Another study in Switzerland on 142 right and left mandible regions by CBCT imaging method (11) reported the frequency of RMC in this

population (25.6%); this frequency is significantly higher than the recent study (9.25%). The reason for this difference can be attributed to ethnic characteristics of the population studied and small size of the samples in this study. In this study, there was no significant relationship between prevalence of RMC and gender, which is consistent with the current study. In another study by Sisman *et al.* on 947 mandibles of 632 patients using panoramic imaging and CBCT (12), the frequency of RMC was 26.7% in CBCT images. The frequency of canal in this study is higher which is likely due to differences in the number of samples and racial differences among the populations studied. Moreover, there was no significant relationship between gender and frequency of RMC as well as gender and frequency of unilateral canals in the right or left mandible, which is consistent with our study (12). In a study by Patil *et al.* in Japan (9) on CBCT images, 171 patients were examined and frequency of RMC was 75.4%, which is significantly different from the frequency of RMC in the recent study (9.25%). The reason for this can be racial and genetic differences or small number of sample cases. However, Patil *et al.* reported the majority of MRCs (56.7%) in the mandibular lingual half, which is similar to our observations (lingual inclination of canal in 57.9% of cases). In a study by Filo *et al.* in Switzerland (1), 680 cases of CBCT images were reviewed. This study is similar to the present study in terms of methodology which is review of CBCT images, but the canal frequency was 16.2%, which is different from the current study (9.25%). This difference can be due to genetic characteristics of the population studied and high sample size in this study. A study by Capote *et al.* (2015) in Brazil focused on panoramic images of 500 patients (23). They

estimated the prevalence of canal at 8.8%. This study was not similar to the recent study in terms of methodology because the recent study was performed on CBCT images, which is more precise because of its three dimensionality. A study by Lizio *et al.* in Italy (24) on CBCT images of 187 patients determined the frequency of RMC at 16%, which is not consistent with results of the recent study. This difference can be due to differences in genetic characteristics of the studied populations and unequal sample size in these two studies. In another study by Kawai *et al.* in Japan (2), CBCT images of 46 dry cadaveric mandibles were reviewed, and canal frequency was determined at 52%, which has a clear difference with frequency of the recent study; this difference can be due to small sample size of this study and genetic differences between the two studies. In the Ossenberg study, which is one of the first studies in this area, the frequency of RMC has been reported in different societies based on different races. In this study, the highest prevalence was observed in the Eskimo and European-Canadian populations (8.2-9.1%) and the lowest was related to the Northeast Asia and Japan (3.2%). Ossenberg also categorized RMC into three different types A, B and C; the most common is A and C is the least common (about 2%). In type A, which is the most common type, RMC is separated from the main mandibular canal and leaves the retromolar foramen through the posterior-upper route. In type B, RMC exist the retromolar foramen through the anterior upper route after being separated from the main mandibular canal. In type C, which is the rarest type, the vessels and nerves in this canal are distinguished by a distinct foramen and enters the ramus in the anterior mandibular foramen and leaves the retromolar foramen downward and forward (11). In some

similar studies (8, 10), type III or C canals have been identified, with frequency ranging from 2 to 6% of total RMCs. The arteries in this canal are distinguished by a foramen and

enter the ramus in the anterior mandibular foramen and it leaves the retromolar foramen downward and forward (Figure 8).

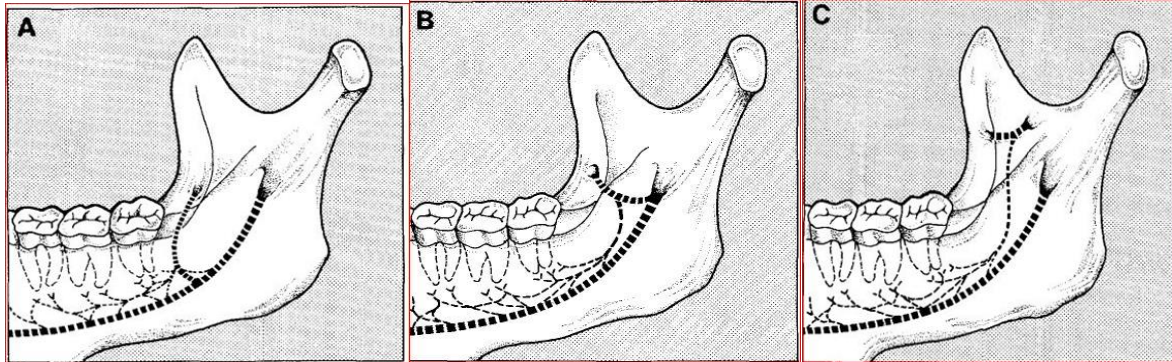


Figure 8: Types of retromolar canal from Ossenberg perspective: A: Type A, B: Type B, C: Type

In the recent study, no case of type III canal was observed due to very low incidence of this type of canal. In the present study, the most common type of RMC was called type I, which is categorized as category A of the Ossenberg classification. In our study, type II RMC is a canal which moves forward after being separated from the main mandibular canal and reaches the root of molar mandibular teeth. This type of canal lacks retromolar foramen or the presence of retromolar foramen is not proved in CBCT images. It is noteworthy that this type of canal has been noted in Patil et al (10) and Rashsuren et al (25).

Conclusion

RMC is important in performing anaesthetic and mandibular retromolar surgeries and its damage leads to extra bleeding, paraesthesia and traumatic neuroma. This canal may also be confused with border of a cystic or pathological lesion in panoramic images. Therefore, it is recommended to use CBCT imaging technique, which is the best and most accurate method for detecting and

determining RMC route in mandibular surgeries and in suspected lesion in the retromolar region.

Suggestions

Due to contradiction of results in several studies, it is suggested to use secondary studies, such as systematic review of references and meta-analysis for definitive conclusions in future studies.

Conflict of interest

The authors declare that there is no conflict of interest.

Highlights

- 1) The current knowledge: RMC is important in performing anaesthetic and mandibular retromolar surgeries.
- 2) What is new here: CBCT imaging technique is the best and most accurate method for detecting RMC. Prevalence of RMC differs in several studies due to several populations.

References

1. Filo K, Schneider T, Kruse AL, Locher M, Gratz KW, Lubbers HT. Frequency and anatomy of the retromolar canal - implications for the dental practice. *Swiss Dent J.* 2015;125(3):278-92.
2. Kawai T, Asaumi R, Sato I, Kumazawa Y, Yosue T. Observation of the retromolar foramen and canal of the mandible: A CBCT and macroscopic study. *Oral Radiology.* 2011;28(1):10-4. [DOI:10.1007/s11282-011-0074-9]
3. Potu BK, Kumar V, Salem AH, Abu-Hijleh M. Occurrence of the retromolar foramen in dry mandibles of South-eastern part of India: a morphological study with review of the literature. *Anatomy research international.* 2014;2014:296717. [DOI:10.1155/2014/296717]
4. Motamedi MH, Gharedaghi J, Mehralizadeh S, Navi F, Badkoobeh A, Valaei N, et al. Anthropomorphic assessment of the retromolar foramen and retromolar nerve: anomaly or variation of normal anatomy? *Int J Oral Maxillofac Surg.* 2016;45(2):241-4. [DOI:10.1016/j.ijom.2015.10.017]
5. Naitoh M, Nakahara K, Suenaga Y, Gotoh K, Kondo S, Arijji E. Variations of the bony canal in the mandibular ramus using cone-beam computed tomography. *Oral Radiology.* 2010;26(1):36-40. [DOI:10.1007/s11282-009-0030-0]
6. Blanton PL, Jeske AH. The key to profound local anesthesia: neuroanatomy. *J Am Dent Assoc.* 2003;134(6):753-60. [DOI:10.14219/jada.archive.2003.0262]
7. Boronat Lopez A, Penarrocha Diago M. Failure of locoregional anesthesia in dental practice. Review of the literature. *Med Oral Patol Oral Cir Bucal.* 2006;11(6):E510-3.
8. Han SS, Hwang YS. Cone beam CT findings of retromolar canals in a Korean population. *Surg Radiol Anat.* 2014;36(9):871-6. [DOI:10.1007/s00276-014-1262-1]
9. Han SS, Park CS. Cone beam CT findings of retromolar canals: Report of cases and literature review. *Imaging science in dentistry.* 2013;43(4):309-12. [DOI:10.5624/isd.2013.43.4.309]
10. Patil S, Matsuda Y, Nakajima K, Araki K, Okano T. Retromolar canals as observed on cone-beam computed tomography: their incidence, course, and characteristics. *Oral Surg Oral Med Oral Pathol Oral Radiol.* 2013;115(5):692-9. [DOI:10.1016/j.oooo.2013.02.012]
11. Ossenberg NS. Retromolar foramen of the human mandible. *Am J Phys Anthropol.* 1987;73(1):119-28. [DOI:10.1002/ajpa.1330730112]
12. Sisman Y, Ercan-Sekerci A, Payveren-Arikan M, Sahman H. Diagnostic accuracy of cone-beam CT compared with panoramic images in predicting retromolar canal during extraction of impacted mandibular third molars. *Med Oral Patol Oral Cir Bucal.* 2015;20(1):e74-81. [DOI:10.4317/medoral.19930]
13. von Arx T, Hanni A, Sendi P, Buser D, Bornstein MM. Radiographic study of the mandibular retromolar canal: an anatomic structure with clinical importance. *J Endod.* 2011;37(12):1630-5. [DOI:10.1016/j.joen.2011.09.007]
14. Schejtman R, Devoto FC, Arias NH. The origin and distribution of the elements of the human mandibular retromolar canal. *Arch Oral Biol.* 1967;12(11):1261-8. [DOI:10.1016/0003-9969(67)90127-6]
15. Narayana K, Nayak UA, Ahmed WN, Bhat JG, Devaiah BA. The retromolar foramen and canal in south Indian dry mandibles. *Eur J Anat.* 2002;6(3):141-6.
16. Pyle MA, Jasinevicius TR, Lalumandier JA, Kohrs KJ, Sawyer DR. Prevalence and implications of accessory retromolar foramina in clinical dentistry. *Gen Dent.* 1999;47(5):500-3; quiz 4-5.

17. Senthil Kumar S, D. K. A Study on the incidence of Retromolar Foramen and Canal in Indian Dried Human Mandibles and its Clinical Significance. *International Journal of Anatomical Sciences* 2010. 14-6 p.
18. Athavale SA, Vijaywargia M, Deopujari R, Kotgirwar S. Bony and Cadaveric Study of Retromolar Region 2013. 14-8 p.
19. J. M, Ramakrishna A, Bindhu.S, N R, A M. Prevalence of retromolar foramen in human mandibles and its clinical significance. 2014. 553-6 p.
20. Jawed M, Sufia, Kumar P, Nafees, Avanish, Binod, et al. A MORPHOLOGICAL STUDY OF RETROMOLAR FORAMEN AND CANAL IN INDIAN DRIED MANDIBLES 2014.
21. Alves N, Deana NF. Anatomical and radiographical study of the retromolar canal and retromolar foramen in macerated mandibles. *International journal of clinical and experimental medicine*. 2015;8(3):4292-6.
22. Sawyer DR, Kiely ML. Retromolar foramen: a mandibular variant important to dentistry. *Annals of dentistry*. 1991;50(1):16-8.
23. Capote TS, Goncalves Mde A, Campos JA. Retromolar Canal Associated with Age, Side, Sex, Bifid Mandibular Canal, and Accessory Mental Foramen in Panoramic Radiographs of Brazilians. *Anatomy research international*. 2015;2015:434083. [DOI:10.1155/2015/434083]
24. Lizio G, Pelliccioni GA, Ghigi G, Fanelli A, Marchetti C. Radiographic assessment of the mandibular retromolar canal using cone-beam computed tomography. *Acta odontologica Scandinavica*. 2013;71(3-4):650-5. [DOI:10.3109/00016357.2012.704393]
25. Rashsuren O, Choi JW, Han WJ, Kim EK. Assessment of bifid and trifid mandibular canals using cone-beam computed tomography. *Imaging science in dentistry*. 2014;44(3):229-36. [DOI:10.5624/isd.2014.44.3.229]

How to cite:

Sarikhani Khorami KH, Ezoddini Ardakani F, Safi Y, Baghestani M: Prevalence, dimension and location of retromolar canal on cone beam computed tomography: An Analytical cross sectional study. *Jorjani Biomedicine Journal*. 2019; 7(3): 68-79.